

Arthrography (Joint x-ray)

This procedure is reviewed by a physician with expertise in the area presented and is further reviewed by committees from the American College of Radiology (ACR) and the Radiological Society of North America (RSNA), comprising physicians with expertise in several radiologic areas.

What is Arthrography?

Arthrography is the x-ray examination of a joint that uses a special form of x-ray called fluoroscopy and a contrast material containing iodine.

An x-ray (radiograph) is a painless medical test that helps physicians diagnose and treat medical conditions. Radiography involves exposing a part of the body to a small dose of ionizing radiation to produce pictures of the inside of the body. X-rays are the oldest and most frequently used form of medical imaging.

Fluoroscopy makes it possible to see internal organs in motion. When iodine is injected into the soft tissue surrounding a joint, it appears bright white on an arthrogram, allowing the radiologist to assess the anatomy and function of the joint.

What are some common uses of the procedure?

Arthrographic images help physicians evaluate alterations in structure and function of a joint and help to determine the possible need for treatment, including surgery or joint replacement.

The procedure is most often used to identify abnormalities within the:

- shoulder
- wrist
- hip
- knee
- ankle

The procedure is also used to help diagnose persistent, unexplained joint pain or discomfort.

How should I prepare?


No special preparation is necessary before arthrography. Food and fluid intake do not need to be restricted.

You should inform your physician of any medications you are taking and if you have any allergies, especially to contrast materials. Also inform your doctor about recent illnesses or other medical conditions.

You may be asked to remove some or all of your clothes and to wear a gown during the exam. You may also be asked to remove jewelry, eye glasses and any metal objects or clothing that might interfere with the x-ray images.

Women should always inform their physician or x-ray technologist if there is any possibility that they are pregnant. Many imaging tests are not performed during pregnancy because radiation can be harmful to the fetus. If an x-ray is necessary, precautions will be taken to minimize radiation exposure to the baby.

What does the equipment look like?



The equipment typically used for this examination consists of a box-like structure containing the x-ray tube and fluoroscopic equipment that sends the x-ray images to a

television-like monitor for viewing that is located in the examining room or in a nearby room. This structure is suspended over a table on which the patient lies. A drawer under the table holds the x-ray film or image recording plate that captures the images.

Other equipment necessary for performing arthrography include a variety of needles, syringes and a water-soluble contrast material.

How does the procedure work?

X-rays are a form of radiation, like light or radio waves that can be focused into a beam. X-rays pass through most objects, including the body. Once it is carefully aimed at the part of the body being examined, an x-ray machine produces a small burst of radiation that passes through the body, recording an image on photographic film or a special image recording plate.

Fluoroscopy uses a continuous x-ray beam to create a sequence of images that are projected onto a fluorescent screen, or television-like monitor. When used with a contrast material, which clearly defines the area being examined by making it appear bright white, this special x-ray technique makes it possible for the physician to view internal organs in motion. Still images are also captured and stored either on film or electronically on a computer.

X-ray images are maintained as hard film copy (much like a photographic negative) or, more likely, as a digital image that is stored electronically. These stored images are easily accessible and are sometimes compared to current x-ray images for diagnosis and disease management.

How is the procedure performed?

This examination is usually done on an outpatient basis.

The patient is positioned on the examination table and x-rays are taken of the joint to be compared later with the arthrograms.

Next, the skin around the joint is cleansed with antiseptic and a local anesthetic is injected into the area. A needle with an aspiration syringe is then inserted into the joint space. The radiologist, a physician specifically trained to supervise and interpret radiology examinations, will use the syringe to drain the joint fluid, which may be sent to a laboratory for analysis. Next, the contrast material and – sometimes – air are injected into the joint space and the needle is removed to prevent the contrast material and/or air from escaping. The patient will be asked to move the affected joint to distribute the contrast material throughout the space. Still images are then obtained with the joint in various positions.

The examination is usually completed within 45 to 60 minutes.

What will I experience during and after the procedure?

Your joint area will be numbed so you do not feel anything related to the arthrographic procedure. Initially, you may experience a slight pinprick and momentary burning as the anesthesia is injected into the joint area. You may feel a fullness as the joint is filled and hear gurgling when the joint is moved.

After the examination, you may experience swelling and discomfort or hear a crackling noise in the joint. You may apply ice to the joint to reduce swelling if it is bothersome. A mild over-the-counter analgesic can be taken for pain. These symptoms usually disappear after 48 hours. Contact your doctor if they persist after two days.

Vigorous exercise is not recommended for 12 hours after the exam.

Who interprets the results and how do I get them?

A radiologist, a physician specifically trained to supervise and interpret radiology examinations, will analyze the images and send a signed report to your primary care or referring physician, who will share the results with you.

What are the benefits vs. risks?

Benefits

- Arthrography is particularly effective for detecting tears or lesions of the structures and ligaments of the joints, especially the knee, wrist and elbow, as well as rotator cuff tears or damage from a shoulder dislocation.
- No radiation remains in a patient's body after an x-ray examination.
- X-rays usually have no side effects.

Risks

- There is always a slight chance of damage to cells or tissue from radiation. However, the radiation risk is very low compared with the potential benefits.
- Patients who have known allergies to iodine may have an adverse reaction to the contrast material. Because the contrast material is put in a joint and not a vein, allergic reactions are rare, although in some cases, mild nausea to severe cardiovascular complications may result.
- Women should always inform their physician or x-ray technologist if there is any possibility that they are pregnant.

A Word About Minimizing Radiation Exposure

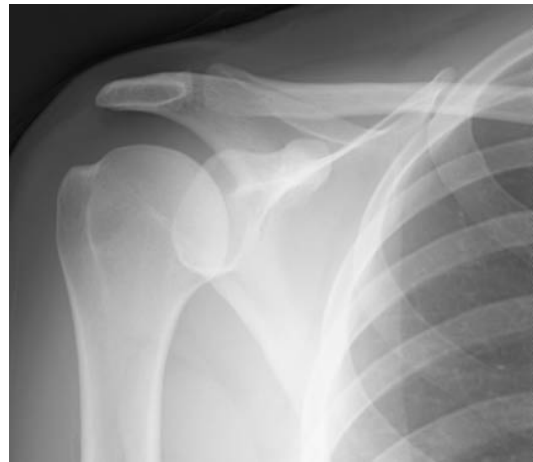Special care is taken during x-ray examinations to use the lowest radiation dose possible while producing the best images for evaluation. National and international radiology protection councils continually review and update the technique standards used by radiology professionals.

State-of-the-art x-ray systems have tightly controlled x-ray beams with significant filtration and dose control methods to minimize stray or scatter radiation. This ensures those parts of a patient's body not being imaged receive minimal radiation exposure.

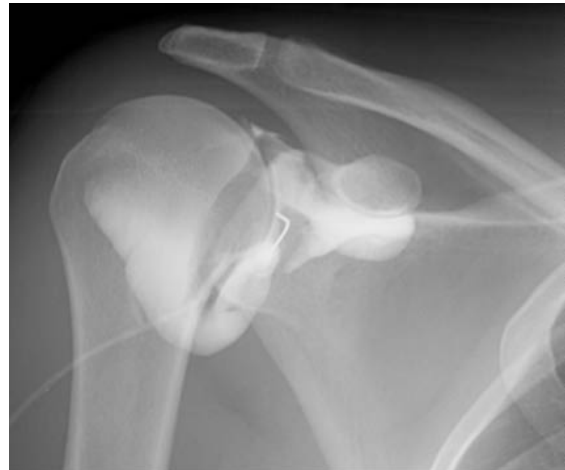What are the limitations of Arthrography?

The limitations of arthrography include:

- Partial tears of the rotator cuff may not be detected
- Although tears of the ligaments and menisci will be detected within the joint, other injuries will not be detected including bruising of the bone and ligaments outside the joint. MRI may be useful in evaluating these types of injuries.



An x-ray of the right shoulder prior to injection of contrast material.



Iodine contrast material has been injected into the shoulder joint - this is a shoulder arthrogram.

Disclaimer:

This information is copied from the RadiologyInfo Web site (<http://www.radiologyinfo.org>) which is dedicated to providing the highest quality information. To ensure that, each section is reviewed by a physician with expertise in the area presented. All information contained in the Web site is further reviewed by an ACR (American College of Radiology) - RSNA (Radiological Society of North America) committee, comprising physicians with expertise in several radiologic areas.

However, it is not possible to assure that this Web site contains complete, up-to-date information on any particular subject. Therefore, ACR and RSNA make no representations or warranties about the suitability of this information for use for any particular purpose. All information is provided "as is" without express or implied warranty.

Please visit the RadiologyInfo Web site at <http://www.radiologyinfo.org> to view or download the latest information.

Copyright © 2006 Radiological Society of North America, Inc.
Send comments via email to: webmast2@rsna.org