

Emerging Technologies in Breast Cancer Detection

By Andrew P. Smith, PhD, Patricia A. Hall, Donna M. Marcello, RT (R) (M)

In the U.S., breast cancer mortality is second only to that of lung cancer. For women ages 40-55, it is the leading cause of death. In 2004, an estimated 40,110 women died of breast cancer.¹ Because of its role in early tumor detection, mammography has played a substantial role in reducing this mortality rate by 20% in the last decade. While screening mammography is recognized as the most effective method for early detection of breast cancer, this modality has the following limitations:

- Up to 20% false-negative rates, where mammography fails to detect cancers.²
- Up to 12% false-positive rates.³
- Inadequate detection of cancer in women with dense breast tissue. Mammography detects approximately 90% of tumors in women over 50, but only 60% of tumors in women under the age of 50.⁴
- Lack of specificity, where mammography cannot distinguish between benign and cancerous breast lesions.

These limitations are the driving force behind efforts to refine existing mammography technologies and develop new ones offering improved detection of breast cancer.

Some of the more promising new breast imaging technologies

include full-field digital mammography (FFDM), computer-aided detection (CAD), full-field digital tomosynthesis, and new uses for breast magnetic resonance imaging (MRI) and ultrasound. Emerging technologies include contrast mammography; nuclear imaging modalities, such as breast positron emission tomography (PET) and scintimammography; near infrared optical imaging platforms; new applications for breast thermography; and bioelectrical imaging technologies. Another trend is acquiring co-registered images from complementary modalities, such as full-field ultrasound coupled to FFDM.

This article surveys several of these promising new technologies with an emphasis on those that are either currently approved by the U.S. Food and Drug Administration (FDA) or are sufficiently far along in their development that we can expect to see their clinical applications in the near term (Table 1).

The pathway from technical innovation to accepted clinical practice is long, arduous, and costly. Those who evaluate the potential of new technologies consider many factors—clinical need, technical performance, economic issues, and patient and societal perspectives. After the regulatory hurdles are run, and reimbursement rates have been argued out and defined, the adoption of new technologies will depend on whether patients and their healthcare providers find them acceptable.

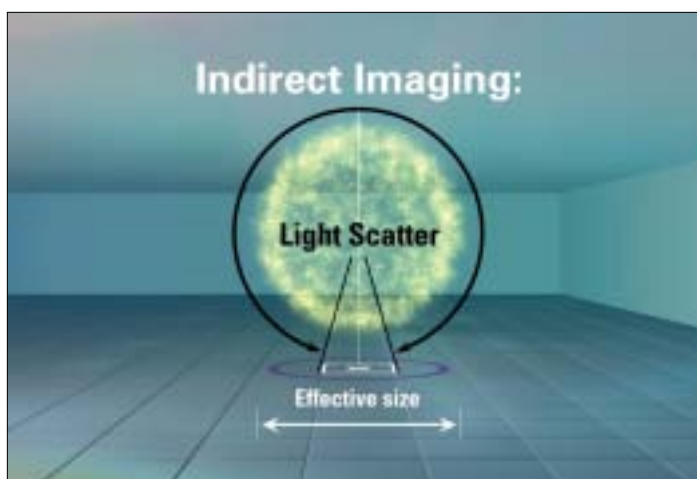


Figure 1. Indirect-Conversion Detectors.

Indirect-conversion detectors utilize a layer to absorb the x-ray and generate light photons, which are detected by a photodiode array. Because light is involved, scatter is a problem.




Figure 2. Direct-Conversion Detectors.

Direct-conversion detectors use a photoconductor to absorb the x-ray and directly generate an electronic signal. No intensifying screens, intermediate processes, or additional steps are required.

Table 1. New and Near-Term Technologies for Breast Cancer Detection.

Technology	Description
Bioelectric Imaging	A low level of electricity is introduced into the body using an electrode array on the surface. Sensors in a non-invasive probe are placed on the breast and then measure the resulting electric field.
Breast Thermography	An infrared camera is coupled with image processing hardware to track the temperature of blood as it flows into the breast and to identify areas of angiogenesis.
Computer-Aided Detection (CAD)	Computer algorithms are used to identify areas on the mammogram containing physical characteristics associated with cancer that may warrant a second review by the radiologist.
Contrast-Enhanced Mammography	X-ray images are made of the breast following administration of an iodinated contrast medium. The images highlight areas of high blood flow and increased vascularity, which is often associated with the rapid growth of tumors.
Full-Field Digital Mammography (FFDM)	Uses traditional x-ray generators and tubes to produce an x-ray beam just like conventional film mammography. The difference is that the radiation strikes a digital image. The x-ray signal is converted into digital information that can be stored electronically, transmitted, displayed, analyzed, and manipulated in a number of ways. The systems allow image processing and offer ease of image storage and retrieval. Facilitates CAD, digital tomosynthesis, and telemammography.
Magnetic Resonance Imaging	Image generated by signals from excitation of nuclear particles in a magnetic field. Breast tumors show increased uptake of contrast agent. Benefits in detection: detection of multiple malignancies, invasive lobular carcinoma, recurrent cancers, and screening for high-risk women with dense breasts.
Near Infrared Optical Imaging	Transmission of near infrared light through the breast is measured.
Nuclear Imaging	This includes both position emission tomography (PET) and single photon imaging (scintimammography). Both methods use radioactive tracers to identify regions in the body with altered increased metabolic activity. The preferential uptake of these tracers occurs because tumors metabolize at a higher rate than normal tissue. The images differentiate tissues based on the functional capacity of tissue behavior.
Tomosynthesis and 3D Imaging	Acquisition of multiple images from many angles, typically around 11 at about a ± 15 -degree range, with the data processed to generate tomographic slices. These images will exhibit reduced interference from overlapping structures. Preliminary studies show that these acquisitions can be performed with doses similar to screening mammography, and that the images offer information improved lesion visibility not available with conventional 2D imaging.
Ultrasound	Use of high-frequency sound waves to generate an image. While ultrasound is commonly used today in diagnostic mammography, studies suggest potential for increased use in screening, especially for women with dense breasts.

Full-Field Digital Mammography⁵

First commercialized in the U.S. in 2000, FFDM systems use digital detectors to convert x-ray photons to digital signals for display on high-resolution monitors. These systems offer capabilities not provided by conventional screen-film mammography.

One of the most attractive features offered by digital mammography is its ability to use a variety of tools to manipulate images. Brightness and contrast can be adjusted, images can be inverted, and digital magnification can be applied to selected regions of the image. Digital mammography also provides the following advantages over screen-film mammography:

- The images are insensitive to exposure variations, so retakes are minimized.
- Reduces exam times.
- Image processing provides improved visibility from the chest wall to the skin line.
- Reduces storage space requirements.
- Transfers information more easily.
- Enables transfer of information to remote locations.

Currently, there are three FDA-approved systems available in the U.S. These use three different detector technologies: indirect-conversion flat panel, indirect-conversion slot-scanning, and direct-conversion flat panel. Other technologies under

development, but not currently approved for use in the U.S., include computed radiography (CR) and the photon-counting slit system.

Indirect-Conversion Digital Detectors

Indirect-conversion detectors, shown in Figure 1, use a scintillator layer composed of cesium iodide doped with thallium [CsI(Tl)] to absorb the incident x-rays and convert its energy to light. An array of thin-film diodes converts light photons to electronic signals that are captured using thin-film transistors.

Computed Radiography is a method of indirect-conversion imaging that is proposed for digital mammography. Not currently available in the U.S., it uses storage phosphor plates to latently store the absorbed x-ray energy, which is released in the form of light using a scanning laser beam in a special plate reader.

CR mammography works in a manner similar to screen-film mammography. Instead of a standard screen-film cassette, it uses a digital cassette composed of a photostimulable phosphor plate encased in an 18 cm x 24 cm or 24 cm x 30 cm cassette. The phosphor plate has a radiographic screen containing a special class of phosphors which, when exposed to x-rays, stores the latent image as a distribution of electron charges. Exposed digital plates are fed into a processor, which uses laser light stimulation to release the electronic charges as light. This light is converted to an electronic signal. The electronic signal is transmitted to a computer for image reconstruction, storage, and display or to a laser printer for production of a hardcopy film. To prepare the digital cassette to store another latent image, the digital plate is exposed to light using a scanning laser beam in a special plate reader.

Slot-scanning systems are another form of indirect conversion detectors. A slot scanner uses a narrow, long detector that scans across the breast during the x-ray exposure to acquire a full-field image, unlike large area detectors that image the entire field in a single flash exposure. One such slot-scanning system is currently approved for use in the U.S. The slot-scanning detector, size 1 cm x 22 cm, is composed of a linear array of charge-couple devices (CCD) coupled to a cesium iodide x-ray scintillator. A fan beam of x-rays, moving in sequence with the CCD array, scans the breast, and x-rays are absorbed by the scintillator and converted to light. The light is then converted to electronic signal.

Direct-Conversion Digital Detectors

All commercial direct-conversion detectors, as illustrated in Figure 2, use amorphous selenium as a photoconductor to absorb the x-rays and directly generate an electronic signal. Under the influence of an external electric field, holes (or electrons, depending upon the polarity of the applied field) drift towards a pixel electrode and are collected on a pixel capacitor.

One type of direct conversion detector under development is known as a photon counting system. Not currently approved

for use in the U.S., this system is based on direct-capture slit scanning detector technology. Slit scanners are like slot scanners, except that the detector is only 1 pixel wide, as opposed to the 1 cm size for slot scanners. Like slot scanners, they need to scan across the breast to acquire an image. Because the detector is so narrow and has extremely low efficiency, several of them are usually assembled into a multiple-slit module. The x-rays in each of the slit detectors are absorbed in a layer of silicon crystal and converted directly to electronic signal by an immediate photon counting technology. It differs from all the other systems so far mentioned, in that each photon is detected and counted individually, as opposed to the more conventional methods of charge integration, where only the total number of photons hitting the detector during the entire exposure is measured.

All of these systems generate a digital image, albeit through different means. Following the generation of the digital image, image processing is applied. The purpose of the processing is to allow better visualization of all areas of the image. Current screen-film mammograms suffer from chest wall areas appearing light and skin line areas dark. Through computer algorithms, better appearance in all breast regions can be achieved.

Digital mammography is still a relatively new modality, and advances in image processing and display technologies are being made rapidly. Although large, definitive clinical trials are needed to demonstrate this modality's clinical efficacy as compared to screen-film mammography, many users are realizing benefits in terms of clinical care and practice management.

Digital mammography also serves as the platform for advanced applications including contrast enhanced mammography, full-field digital tomosynthesis, and ultrasound fusion. These technologies are currently under development in the U.S..

Contrast-Enhanced Mammography

Tumor formation is associated with an increased formation of blood vessels, or angiogenesis. Contrast-enhanced mammography has the potential to detect early stage breast malignancies by detecting signs of angiogenesis and to monitor the effectiveness of anti-angiogenesis drug therapy.

Contrast-enhanced mammography utilizes the basic biological principle that aggressive cancers are associated with increased vascularity. Cancers need the oxygen and food delivered by the blood to thrive and grow. The iodinated contrast agents—the same used in computed tomography (CT) examinations—are administered through an injection in a vein usually in the arm. They distribute throughout the blood system, and x-ray imaging shows increased contrast in areas where they concentrate. This happens because the contrast agents are highly attenuating to x-rays. The images highlight new blood vessel development that often accompanies malignant growth.

There are two common methods of performing contrast mammography imaging: dual energy subtraction and temporal subtraction. In dual energy contrast-enhanced digital subtraction mammography, two images are taken at different energy

levels and subtracted from one another. The subtraction increases visibility of the contrast agent.

In the temporal subtraction approach, a pre-injection mask image is taken, the contrast agent is administered, several post-contrast images are taken at specific intervals and subtraction images (post-contrast images minus the mask image) are processed and evaluated.

Clinical studies are underway in the U.S. to evaluate the effectiveness of contrast-enhanced mammography. Some researchers believe this modality may become an alternative to breast MRI in evaluating difficult-to-interpret mammograms or for high-risk screening. It may also be useful in evaluating multicentric disease in newly diagnosed patients.

Full-Field Digital Tomosynthesis⁶

Tomosynthesis is a method of performing 3D x-ray mammography at doses similar to conventional 2D x-ray mammography. Tomosynthesis acquisition involves acquiring multiple images of a stationary compressed breast at different angles during a short scan. The individual images are then reconstructed into a 3D series of thin high-resolution slices. The slices can be displayed individually or in a dynamic ciné mode. The individual slices reduce tissue overlap and structure noise relative to standard 2D projection mammography, with a total dose comparable to that required for standard screening mammography.

The digital tomosynthesis device offers a number of exciting opportunities, including the possibility of reduced breast compression, improved diagnostic and screening accuracy, 3D lesion localization, and contrast enhanced 3D imaging. Conventional x-ray mammography is a 2D imaging modality. The signal detected receptor is dependent upon the total attenuation of all the tissues above the location. This is illustrated in Figure 3. The two objects (ellipse and star) individually attenuate x-rays passing through them on the way to the image receptor; however, the signal detected represents a summation of their attenuation. In mammography, pathologies of interest are more difficult to visualize because of the clutter of signals from objects above and below. Tomosynthesis is a method of 3D imaging which can reduce this tissue overlap effect.

The basics of tomosynthesis acquisition theory are illustrated schematically in Figure 4. While holding the breast stationary, a number of images are acquired at different x-ray source angles. It can be seen from the figure that the objects at different heights in the substance being x-rayed project differently in the different projections. In this example, the two objects superimpose when the x-rays are at 0°, but the ±15° acquisitions shift the

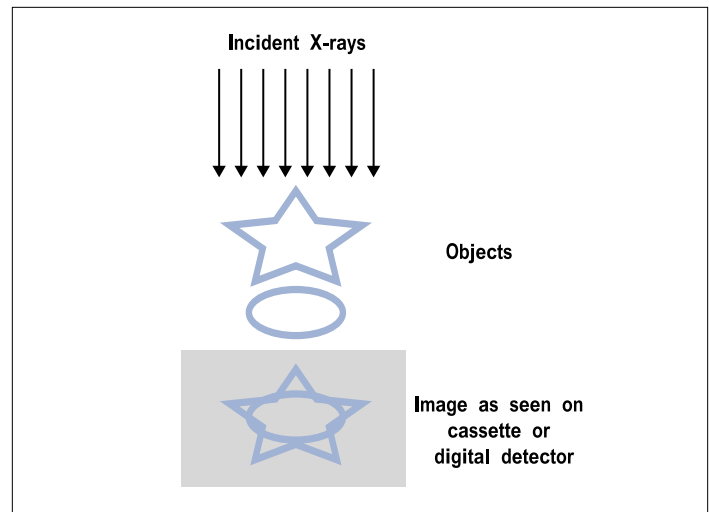


Figure 3. Signal Detection.

With conventional mammography, the signal detected at the location on the image receptor is dependent upon the total attenuation of all the tissues above the location.

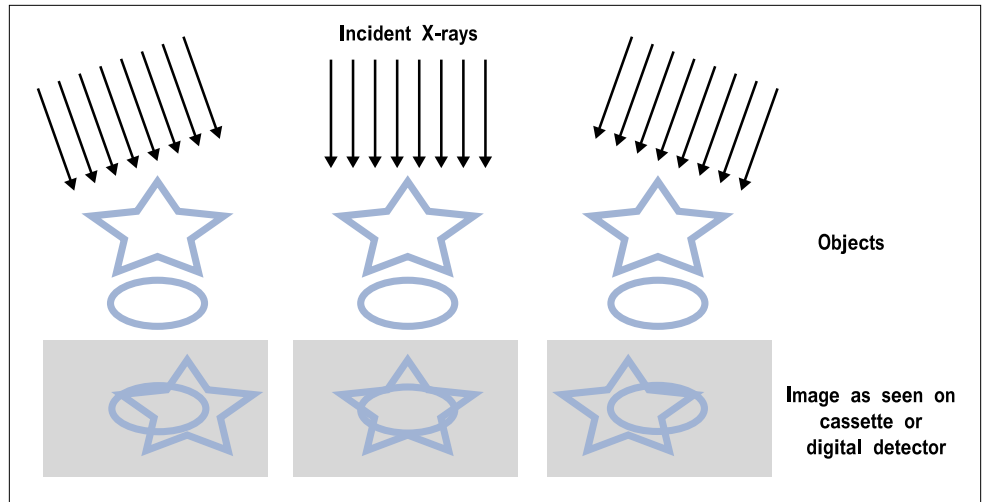


Figure 4. Tomosynthesis Imaging.

With tomosynthesis imaging, images acquired from different angles separate structures at differing heights. Conventional mammography would acquire only the central image.

object's shadows relative to one another in the images.

The final step in the tomosynthesis procedure is reconstructing the data to get 3D information. This is illustrated in Figure 5. In the example on the right side of the figure, the projection images are summed, shifting one relative to another in a specific way that reinforces the ellipsoidal object and reduces the contrast of the starred object by blurring it out. Similarly, in the example on the left side, the same set of acquired projection data can be reconstructed differently, using different shifts of the projection data, to reinforce the star object and blur the ellipse. This method can be used to generate images that enhance objects from a given height by appropriate shifting of the projections relative to one another. Note that additional acquisitions are not required to achieve this; the single set of acquired data can be reprocessed to generate the entire 3D volume set.

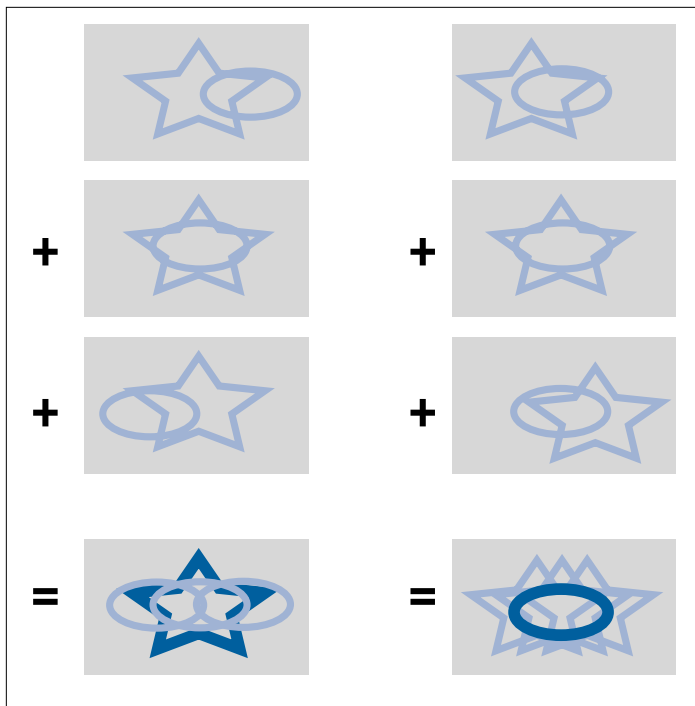


Figure 5. 3D Imaging.
By shifting and adding the acquired projections, 3-D imaging increases the visibility of objects by blurring out objects from other heights.

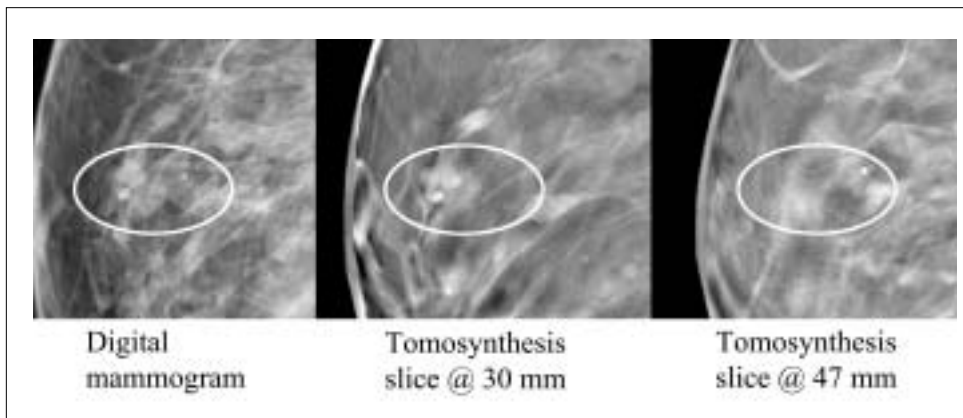


Figure 6. The 3D Nature of Tomosynthesis.
The digital mammogram on the left shows 1 calcification. Slices from the tomosynthesis reconstructions, shown in the 2 right images, show that one calcification is at 30 mm height in the breast, and the other at 47 mm.

Reconstruction

The reconstruction process consists of computing high-resolution images whose planes are parallel to the breast support plates. Typically, these images are reconstructed with slice separation of 1 mm, thus a 5 cm compressed breast tomosynthesis study will have 50 reconstructed slices. Rapid reconstruction time is essential, especially when tomosynthesis is being considered as part of an interventional study, and for this reason it is important to keep the entire post-acquisition processing times as short as possible.

Display Methodology

The reconstructed slices can be displayed similarly to CT

reconstructed slices. The operator can view a single image at a time, or display all the images in a ciné loop. The original projections are identical to standard projection mammograms, albeit at a lower dose, and these can be viewed as well, if desired. The system can also take a normal mammogram under the same compression. In this case, the tomosynthesis slices and the mammogram are completely co-registered, thereby making objects correlated in the two differing image sets. Because the location of a lesion in a tomosynthesis slice completely determines its true 3D coordinate within the breast, biopsy tissue sampling methods can easily be done using the tomosynthesis generated coordinates.

In Figure 6, there are two calcifications visible in the digital mammogram. When one looks at the individual tomosynthesis slices, the distance between the microcalcifications can be measured—in this case, approximately 17 mm. This 3D information is not available in conventional mammography.

Figure 7 shows the improvement in object visibility by the elimination of tissues above and below the object of interest. The tomosynthesis slice clearly shows several lesions that are obscured on the digital mammogram by clutter from other tissue.

Full-Field Digital Mammography/Ultrasound Fusion

Initial efforts are underway to develop prototype systems to achieve high resolution, whole breast 3D ultrasound images that are co-registered with digital mammograms. This technology has the potential to improve specificity in breast imaging studies, particularly in dense breasts. Ultrasound is already used in diagnostic examinations to resolve image ambiguities seen in the screening x-ray mammograms. One difficulty in interpreting the ultrasound images is correlating objects seen in the ultrasound with objects seen in the x-ray images. The fusion systems acquire both

images during the same compression and allow comparison between the two image modalities. The systems work by compressing the breast in the standard way. An x-ray image is taken conventionally. While the breast is still under compression, an ultrasound probe automatically scans across the breast under computerized motor control. Operator variability is reduced with this method, and the ultrasound images are in the same geometry as the mammogram.

Computer-Aided Detection

CAD was approved for use in the U.S. in 1998. It was first used as an adjunct to screen-film mammography. With the emergence of digital mammography, CAD systems for screening

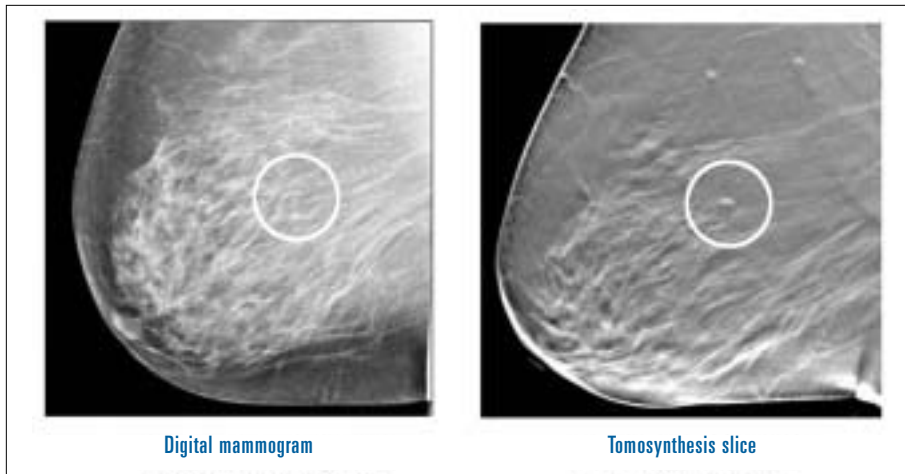


Figure 7. Improvement in Object Visibility Using Tomosynthesis.

mammography consist of sophisticated computer programs designed to recognize physical characteristics of breast cancer, such as microcalcifications and masses. As shown in Figure 8, the outputs of these systems are images with marks highlighting potentially suspicious features.

CAD programs are intended to help radiologists identify suspicious lesions that may otherwise be overlooked. CAD software works similarly to a spellchecker and has the potential to increase the detection of cancer. The interpretation of screening mammograms is particularly challenging, since a large number of cases are viewed to detect a small number of cancers (3-10 cancers per 1,000 women screened). These are often manifest by subtle alterations superimposed upon the complex radiographic structure of the breast. As a result, some cancers are missed.

Studies show that a significant number of cancers (as many as 30%-65%) can be visualized on prior mammograms in retrospective review. Double reading of mammograms by two radiologists can improve the detection rate of cancer (which yields a 4%-15% increase in cancers detected), but this is expensive and time consuming.⁷ The goal of CAD is to improve detection rates in a more efficient and cost-effective manner.

The challenge for CAD programs is to find the proper balance between sensitivity and specificity. Increasing sensitivity can result in too many false positives marked on an image and the radiologist may find this more of an annoyance help. Conversely, if not enough true positives are marked, the system will be offering little help to the radiologist. The low cancer rate per image in screening environment makes this task difficult. Some CAD programs have begun to address this issue by offering physicians choices in sensitivity levels in software.

Magnetic Resonance Imaging

MRI has been used for a wide variety of medical applications since 1985. Early efforts with breast MRI were disappointing; however, the use of intravenous agents with a dedicated breast MR coil represented a clear advance in the technology. MR images are created by recording the signals generated after

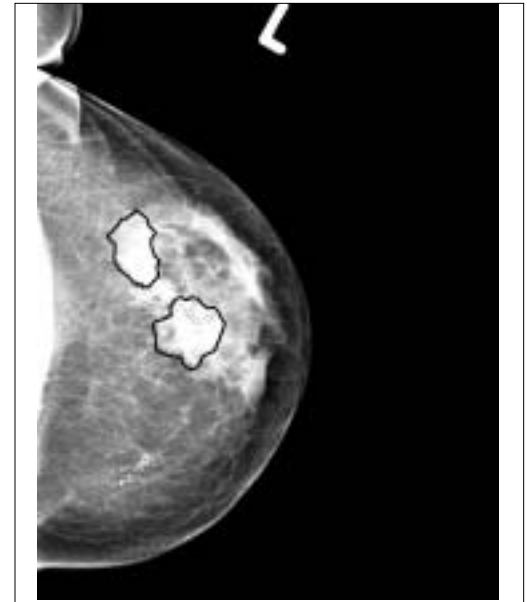

Figure 8 . CAD Algorithms.
CAD algorithms outline suspicious brighten suspicious clusters of so that they stand out.

radio frequency excitation of nuclear particles in tissue exposed to a strong magnetic field. The signals have characteristics that vary according to tissue type.

Most breast MRI uses a contrast agent, gadolinium-DPTA. The basic idea behind this is similar to that discussed with iodinated contrast mammography. The contrast agent, injected into the patient's bloodstream, accumulates in the vascular system, and can locate tumors by highlighting areas containing a dense blood vessel network. Like contrast mammography, usually several scans are taken: one prior to contrast agent injection and one or more after the injection. The pre-contrast and post-contrast images are compared and areas of high uptake of the contrast agent are analyzed.

Today, MRI is a generally accepted diagnostic procedure for a number of breast related indications. Its greatest strength is that it is very sensitive to tumors. If a suspected area does not exhibit contrast agent uptake, the probability that it is malignant is very small. Conversely, its specificity is poorer. If the area does show enhancement, it may or may not be a tumor. Further imaging or biopsy may be needed to resolve the question. MRI is also used to image breast tissue near implants, where x-ray mammography is poor. In addition, it is useful, following breast cancer diagnosis, as a guide for tumor staging, as well as for post-interventional therapy monitoring and detecting local recurrence.

Perhaps its biggest limitations are its costs and the lack of general geographic availability. MRI is also more time-consuming than mammography, both in the acquisition and the readings, and it requires contrast agents.

There is an FDA-approved system designed specifically for breast MRI. Ongoing clinical studies are currently evaluating the

usefulness of MRI screening for high-risk patients or women with mammographically unsuitably dense breasts.

Breast Ultrasound

Each year, mammography is used to screen more than 44 million women in the U.S.. Of those women, 36% (approximately 16 million) are referred for a second, diagnostic test. Many of these women are given a breast ultrasound exam.

Ultrasound waves are high-frequency sound waves that reflect at boundaries between tissues with different acoustic properties. The depth of these boundaries is proportional to the time intervals of reflection arrivals. Thus, ultrasound can map an image of tissue boundaries. Ultrasound can also provide information about blood flow by mapping the amount of acoustic frequency shift as a function of position in tissue; this is the Doppler effect.

Ultrasound holds promise as a method for detection of cancers in women with dense breast tissue, which is often problematic with conventional screen-film mammography. Ultrasound has also assumed an important role in breast imaging, as an adjunct to diagnostic mammography for biopsy guidance, palpable mass evaluation, and serial evaluation of benign masses. In the last few years, great strides have been made in improving image quality and resolution of all ultrasound machines. These improvements were the result of new transducer design technology and advances in electronic signal processing.

A limitation of conventional ultrasound has been its poor ability to detect small calcifications in the breast, or microcalcifications. These microcalcifications range from 50 to several hundred microns in diameter, and they may be an important early indication of breast cancer. Small calcifications with ultrasound are difficult to interpret due to a phenomenon, called “speckle,” that arises from the interaction of the ultrasound field with tissue. In the breast, speckle may produce small bright echoes within tissue that have an appearance quite similar to small calcification, making detection of true calcifications difficult.

Conventional ultrasound generates images using a beam that strikes tissues from a single direction. Recent developments have made it possible to generate an ultrasound image using several beams that strike the tissue from several angles. This technique, called compound imaging, allows for the suppression of artifacts and the reinforcement of real structures. The result is improved contrast and detail resolution with improved visualization of borders and interfaces. However, the use of compound imaging may reduce the display of clinical markers such as shadowing and posterior enhancement.

The detection of tumor blood supply may prove to be important in the differentiation of benign and malignant masses. Doppler ultrasound permits the identification of blood flow within some breast masses, but has limited sensitivity.

Three-dimensional ultrasound permits the examination of a volume of tissue, rather than a single slice. Researchers have

developed innovative techniques for registration of images from 3D data sets, permitting more accurate measurement of tumor volume and comparison of changes in the size of masses over time.

A novel use of ultrasound in the breast currently under development is elastography, which uses information from the ultrasound signal to produce an image displaying the elastic properties of breast tissue. Like palpation, elastography is able to detect and display differences in tissue stiffness. Since most cancers are hard in comparison to the tissues that surround them, elastography provides a high contrast image, in some cases revealing features that may not be visible with conventional ultrasound or mammography.

Although mammography will most likely continue to be the primary means of identifying small calcifications that correlate with certain types of cancer, ultrasound is becoming increasingly useful as an adjunct modality to mammography.

Other Breast Cancer Detection Technologies

There are a number of other FDA-approved products or technologies under development with potential applications in the detection and diagnosis of breast cancer. The following is a brief summary of some of those technologies.

Breast Thermography

Breast thermography received FDA approval in 1982 as an adjunctive breast cancer screening procedure. In breast thermography, an infrared camera is coupled with image processing hardware and software to track the temperature of blood as it flows into the breast and to identify areas of angiogenesis.

Positron Emission Tomography (PET)

PET is used in the U.S. for restaging and evaluating recurrent breast cancer. A number of commercial systems are available for use in breast cancer applications. In PET, a small amount of radioactive glucose, usually 18-fluoro-2-deoxyglucose (FDG), is injected into a vein, and a nuclear camera generates images that highlight areas of high tracer uptake. Like contrast mammography and contrast MRI, glucose accumulates in tissues of high growth. In particular, glucose goes to areas of high glucose utilization or metabolism. Aggressive tumors are a type of tissue in the body where metabolism is rapid. The result of the PET scan is a set of images showing the distribution of the drug in the breast. A number of breast specific PET scanners are currently in development and in early clinical trials to demonstrate efficacy.

Scintimammography

Scintimammography is used as an adjunct to mammography for the detection of breast cancer in patients with dense breasts; with architectural distortions from prior biopsy, surgery, or radiation therapy; that have palpable lesions; or where there have been indeterminate findings on mammography. Scintimammography produces an image of a tumor by using radioac-

tive tracers that are taken up more readily by breast tumors compared to normal breast tissue. The localization of the tracer can be imaged using scintillating (gamma) cameras. Areas with higher uptake activity associated with tumor cells are darker than the rest of the breast.

Recent advances have been made in high-resolution gamma cameras designed specifically for breast imaging. The basic philosophy of scintimammography and PET images are similar; the drugs used are different and the gamma ray energies emitted are different so the physical cameras work on quite different principles. The resolution of scintimammography, on the order of 5-10 mm, is inferior to that of PET's 3-5 mm. There is no clear consensus on which of these nuclear methods is superior. PET systems offer higher resolution; however, PET examinations are extremely expensive, and they are not widely available. Scintimammography is a procedure that can be done at virtually every hospital in the U.S.. The PET tracer is thought to directly measure metabolism and so the biology of PET images is better understood, but the tracer shows poor specificity in separating tumor recurrence from surgical scarring.

Near Infrared Optical Imaging

A number of near infrared optical imaging technologies are currently under development in the U.S., but there are no FDA-approved products at this time. This technology uses light emitting diodes to transmit near infrared light through the breast to produce an image. The systems measure the absorption of light at several different frequencies, and can differentiate oxygenated from de-oxygenated hemoglobin. Image-processing algorithms are then used to highlight areas of vascular development (angiogenesis) and/or hypermetabolism (hemoglobin and oxygen saturation levels). Images have very poor resolution; however, optical scanning is able to penetrate deeply into the breast, uses no radiation, and so is completely non-invasive. A major advantage is patient comfort, because the breast is not compressed.

Bioelectric Imaging

There is a single FDA-approved bioelectric imaging device. This device is used for follow-up of ambiguous mammography results. The technology is based on the different electrical properties between normal and malignant breast tissue. Bioelectric imaging uses a low level of electricity introduced into the body using an electrode array on the surface. Sensors in a non-invasive probe placed on the breast then measure the resulting electric field. Measurements are made over several frequencies to create and display a real-time electrical image of the breast, along with immediate results.

Conclusion

There are many exciting new technologies being applied to the problem of breast cancer detection. All of them are designed to address the accuracy limitations of conventional screen-film mammography. Digital mammography is important as an

enabling technology. It offers advances in image processing, transmission, and display, but also facilitates the development of CAD, 3-D tomosynthesis, and contrast-enhanced mammography. A number of adjunctive imaging technologies, such as MRI, ultrasound, and nuclear imaging, have been seen to offer complementary diagnostic information to the conventional x-ray image. Other advances, such as optical, thermal, and bioelectric imaging, are non-invasive and also complementary to x-ray-based mammography. All these methods promise to improve breast cancer detection.

References

- ¹ 2004 National Cancer Institute. Available at: <http://www.nci.nih.gov/cancertopics/types/breast>.
- ² 2004 National Cancer Institute
- ³ 2004 National Cancer Institute
- ⁴ 2004 National Cancer Institute
- ⁵ Smith, A. Fundamentals of Digital Mammography: Physics, Technology and Practical Considerations. *Radiology Management*. 2003; 25(5): 18-31.
- ⁶ Smith, A. Full-Field Breast Tomosynthesis. Hologic reference paper. 2003. Available from: asmith@hologic.com
- ⁷ Destounis, MD, Stamatia V., et. al. Can Computer-aided Detection with Double Reading of Screening Mammograms Help Decrease the False-Negative Rate? Initial Experience. *Radiology* 2004;232:578-584.

Andrew P. Smith, PhD, is principal scientist at Hologic, Inc., in Bedford, MA, where he is involved in research and development. His previous employment was with Digital Scintigraphics Inc., a nuclear medicine company he cofounded. Prior to that, he attended the Massachusetts Institute of Technology, where he received a bachelor's degree and doctoral degree in physics. He may be contacted at asmith@hologic.com.

Patricia A. Hall is product communications manager for Hologic, Inc., where she is involved in product management for breast imaging products. Her previous employment was with a pharmaceutical research company in roles including business development, clinical trial management, and marketing. She may be contacted at phall@hologic.com.

Donna M. Marcello is a women's health specialist at Hologic, Inc. She has been a mammographer for 25 years. Before joining Hologic, she was a radiology department manager. She may be contacted at dmarcello@hologic.com.

Hologic, Inc.
35 Crosby Drive
Bedford, MA 01730 U.S.A.
T: 781.999.7300
www.hologic.com
marketing@hologic.com